



Access the article online

Quick Response Code



www.jacjournal.org

DOI:https://doi.org/10.51648/jac74

***Corresponding author**

Mr. Bharat Pathak

Assistant Professor; Department of
Anatomy, Ayurveda Campus, Institute of
Medicine, Tribhuvan University, Kirtipur
Kathmandu, Nepal

E-mail: bharat.pathak@ayc.tu.edu.np

Submitted: 29.03.2023

Received: 18.04.2023

Revised: 10.05.2023

Accepted: 24.07.2023

Copyright: © The Author(s) 2023. This is
an open access article under the CC BY NC
license.

**Complete Non-fusion of Sacral Spines: A Rare Anomaly****Bharat Pathak***

Assistant Professor; Department of Anatomy, Ayurveda Campus, Institute of Medicine
Tribhuvan University, Kirtipur, Kathmandu, Nepal

ABSTRACT

Background: Human sacrum is a large triangular bone formed by fusion of five separate sacral vertebrae and their intervertebral disc. The dorsal surface of sacrum presents triangular sacral canal formed by fusion of sacral vertebral foramina. The opening present at the caudal end of the sacral canal is known as sacral hiatus. Sacral hiatus is formed due to failure of fusion of lamina and spinous process of fifth or fourth sacral vertebrae. Spina bifida occulta is a condition resulting due to incomplete fusion of neural arch of vertebrae, mainly in lumbosacral region. When the condition of spina bifida occulta occurs in the sacrum, the level of non-closure becomes variable.

Materials and Methods: A dry human sacrum with full agenesis of the dorsal wall of the sacral canal was identified during regular osteology demonstration lessons for undergraduate BAMS students at Department of Sharir Rachana (Anatomy), Ayurveda Campus, Institute of Medicine, Tribhuvan University, Kathmandu, Nepal. Non-metric differences in spines were thoroughly examined.

Results and Discussion: Spina bifida is the generic term for range of discrete defects of neurulation and subsequent vertebral formation. The various forms of neural tube and vertebral defects have been reported such as craniorachisis, anencephaly and myocele. In this case a spine with complete sacral spina bifida occulta was discovered. The posterior laminae of all sacral vertebrae were completely unfused in this specimen. It's more likely that the sacral region was a groove than a canal. There were no additional abnormalities discovered. Many studies on incidence of spina bifida occulta have been published with mixed results. The frequency reported by researchers and population varies substantially.

Conclusion: The complete agenesis of the dorsal wall of the sacral canal in these variants is critical for diagnosing lower back pain, sciatica, and caudal regression syndrome, as well as avoiding problems from caudal epidural block and other spinal procedures, such as screw placement for spinal fusion.

Key Words: sacrum, spina bifida, non-fusion, sacral spines

INTRODUCTION

Human sacrum is a large triangular bone formed by fusion of five separate sacral vertebrae and their intervertebral disc. It articulates with hip joint laterally to form sacroiliac joint. It forms the posterosuperior wall of the bony pelvis. The apex of sacrum inferiorly articulates with the coccyx to form sacrococcygeal joint whereas its base superiorly articulates with fifth lumbar vertebrae to form lumbosacral joint.¹ Sacrum is larger in males than in females whereas width of ala is more in females than in males. The base of sacrum is divided into central part consisting of body of first sacral vertebrae and lateral part consisting of ala and lateral mass.² Anterior or pelvic surface of sacrum is concave both craniocaudally and transversely to form bowl shaped concavity. The ventral surface presents four transverse ridges indicating the fusion of four sacral vertebrae. On lateral end of ridges four pair of ventral sacral foramina are present.³

The dorsal surface of sacrum is convex in shape. The posterior surface presents five

longitudinally running crests formed by fusion of posterior elements of initial vertebral segments. The most prominent of these crests is the median sacral crest formed by fusion of three or four rudimentary spinous process of sacral vertebrae.^{1,3.}

The dorsal surface of sacrum presents triangular sacral canal formed by fusion of sacral vertebral foramina. The opening present at the caudal end of the sacral canal is known as sacral hiatus. Sacral hiatus is formed due to failure of fusion of lamina and spinous process of fifth or fourth sacral vertebrae. The upper opening of sacral canal is set obliquely.⁴

Spina bifida occulta is a condition resulting due to incomplete fusion of neural arch of vertebrae, mainly in lumbosacral region.⁵ When the condition of spina bifida occulta occurs in the sacrum, the level of non-closure becomes variable.⁶ Non fusion of sacral lamina in midline may cause compression of nerve roots and may result in various clinical problems including lower back pain, may interfere with epidural anesthesia procedure and transpedicular lateral mass screw placement failure. Abnormal spina bifida may result in exposure of structures present in sacral canal.⁷ If there is nonunion of laminae of all the sacral vertebrae, there will be midline gap.⁸ Many writers have found that the structural changes of the sacral hiatus influence the reliability and efficacy of the caudal epidural block. Chronic back pain is commonly treated with a caudal epidural block.⁹

CASE REPORT

We discovered a dry human sacrum with full agenesis of the dorsal wall of the sacral canal during regular osteology

demonstration lessons for undergraduate BAMS students at Department of Sharir Rachana (Anatomy), Ayurveda Campus, Institute of Medicine, Tribhuvan University, Kathmandu, Nepal. Non-metric differences in spines were thoroughly examined. A spine (specimen no: sacrum 005/Anatomy, ACTH) with complete sacral spina bifida occulta was discovered. The specimen's photographs were taken (Fig 1). The posterior laminae of all sacral vertebrae were completely unfused in this specimen. It's more likely that the sacral region was a groove than a canal. There were no additional abnormalities discovered. The specimen is compared with normal sacrum. Photographs of pelvic and dorsal surface of both normal sacrum and sacrum with spina bifida occulta were taken for comparison (Fig 2 and 3).

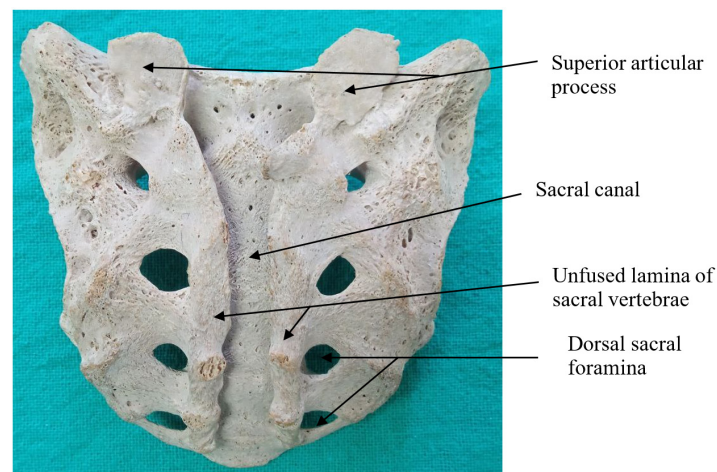


Fig 1: Complete non-fusion of sacral spines (Dorsal View)

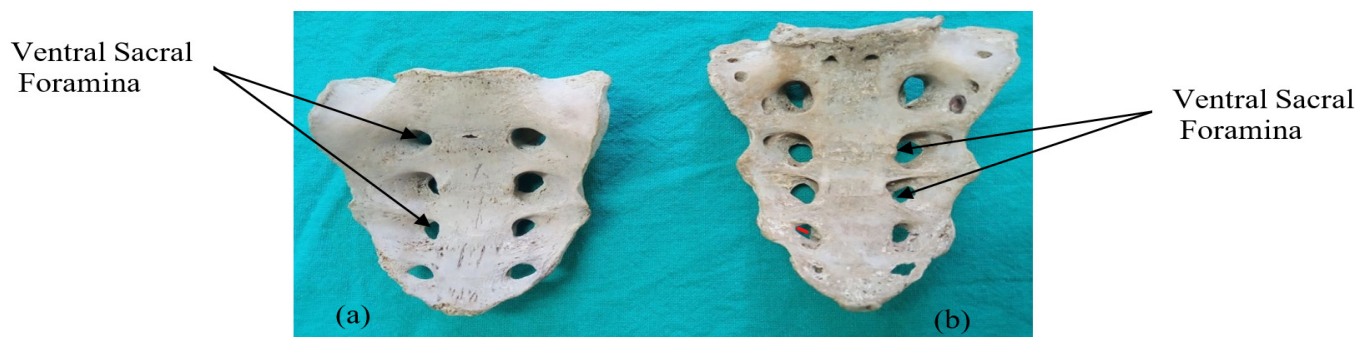

Fig 2: Pelvic surface of sacrum with complete non fusion of sacral

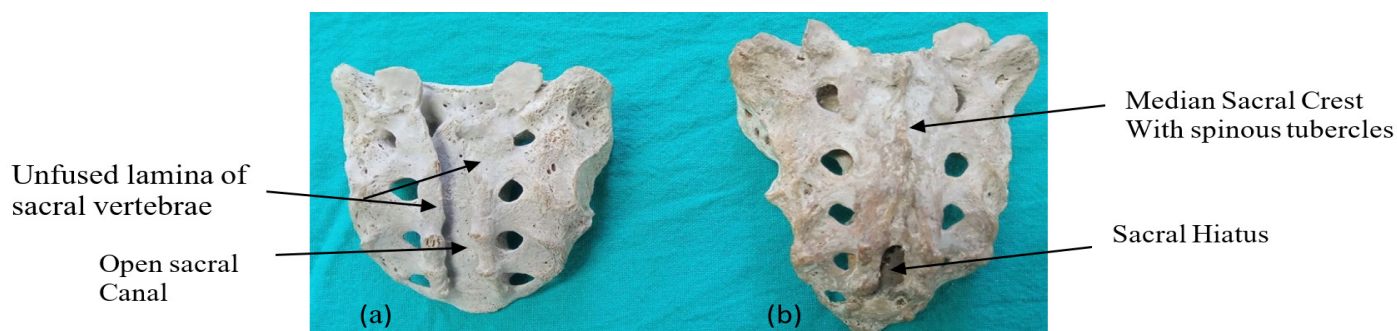


Fig 3: Dorsal surface of sacrum with complete non fusion of sacral spines(a) and

RESULTS AND DISCUSSION

Spina bifida is the generic term for range of discrete defects of neurulation and subsequent vertebral formation.¹⁰ The various forms of neural tube and vertebral defects have been reported such as craniorachisis, anencephaly and myocele.

Total spina bifida of the sacrum is characterized by a lack of induction from the neural tube's roof plate during development, which may involve the expression of the Pax-9, Msx-1, and Msx-2 genes. The neural arches and their pedicles, arising from the dorsal sclerotomal cells, fuse on either side with the centrum and along with other neural arches form a protective roof over the spinal cord. Incomplete closure of bony roof results in a common anomaly called spina bifida occulta.¹¹ It's impossible to tell whether a person had spina bifida occulta (SBO) or spina bifida cystica during their lifetime from their dry bones. Spina bifida is a significant birth abnormality caused by the failure of the halves of the neural vertebral arch to fuse.¹²

A study classified the spina bifida occulta was divided into four types, ranging from type I to type IV. In type I dorsal wall was completely open starting from top of S1 spine up to sacral hiatus, in type II sacral canal is open below S1 up to S5, in type III sacral canal is open below S2 and in type IV dorsal wall is open below S3 up to S5. This study showed that type IV was common among Indian and Australian population.¹³ The sacrum found in this case study is of type I.

Many studies on incidence of spina bifida occulta have been published with mixed results. The frequency reported by researchers and population varies substantially. Table 1 shows the frequency of sacral spina bifida occulta in different studies in different countries.^{10, 14,15,16,17,18,19} With increase in length of sacral spina bifida occulta fusion of body of sacral vertebra becomes more defective.¹³

Table 1: Percentage of total spina bifida occulta in different studies

Author	Total spina bifida occulta percentage
Trotter et al (1944)	1.8
Vinodkumar et al (1992)	1.49
Sekiguchi et al (2004)	1.0
Zarna patel et al (2011)	2.0
Kiran.V.Padeyappanavar (2011)	2.0
Shilpa Nilesh Shewale et al (2012)	0.98
Dharati M Kubarati (2013)	1.65

There is no published literature on frequency of spina bifida occulta in Nepali population, so this study is the first reported case of spina bifida occulta in Nepal.

The sacral spina bifida occulta has a range of clinical relevance from a minor morphological deviation to a major cause of neurological impairments.²⁰ Total spina bifida occulta may be associated with

a number of clinical implications such as change in CSF pressure, short lower limbs, bladder and bowel disorders, meningocele, defective erector spinae and multifidus muscle attachment, prone to fracture and failure of caudal epidural block (CEB).^{13,15,21,22,23.}

Because of the cyst like sac that is associated with these abnormalities, a severe variety of spina bifida including protrusion of the spinal cord and/or meninges via defects in the vertebral arches is referred to as spina bifida cystica. Spina bifida cystica affects about one in every 1000 babies born. In some circumstances, neurological signs are evident.¹²

The planning of screw fixation in the presence of spina bifida would undoubtedly be a difficulty for neurosurgeons.^{7,20} The abnormality has a clinical significance for the CEB, which is used to diagnose and treat lumbar spine problems as well as to manage chronic back pain.^{15,20,24,25.}

CONCLUSION

The complete agenesis of the dorsal wall of the sacral canal in these variants is critical for diagnosing lower back pain, sciatica, and caudal regression syndrome, as well as avoiding problems from caudal epidural block and other spinal procedures, such as screw placement for spinal fusion. This might be the first case reported from Nepal so it will be helpful for anesthetists and clinicians for consideration while treating the disease.

CONFLICTS OF INTEREST: None

SOURCE OF FUNDING: None

ACKNOWLEDGEMENT: None

REFERENCES

1. Standring S, editor. Gray's Anatomy - The Anatomical Basis of Clinical Practice. 40th ed. London: Churchill Livingstone Elsevier; 2008:724-728.
2. Agur AM, Dalley AF. Grant's atlas of anatomy. Lippincott Williams & Wilkins; 2009.
3. Cheng JS, Song JK. Anatomy of the sacrum. Neurosurgical focus. 2003;15(2):1-4. DOI:10.3171/foc.2003.15.2.3 PMID:15350034
4. Esses SE, Botsford DJ. Surgical Anatomy and Operative Approaches to the Sacrum, in Frymoyer JW, Ducker TB, Hadler NM, et al (eds): The Adult Spine: Principles and Practice, ed 2. Philadelphia: Lippincott-Raven; 1997;Vol 2:2329-2341.
5. Brailsford JF. Deformities of the lumbosacral region of the

- spine. British Journal of Surgery. 1929;16(64):562-627. DOI:[10.1002/bjs.1800166405](https://doi.org/10.1002/bjs.1800166405)
6. Romanes GJ. Cunningham's Textbook of anatomy. 12th ed. Oxford: Oxford University Press; 1981.
7. Srijit D, Shipra P. Spina bifida with higher position of sacral hiatus: a case report with clinical implications. Bratislavske lekarske listy. 2007;108(10-11):467-469.
8. Vishal K, Vinay KV, Remya K, Kumar A, Shishir K. High sacral hiatus with non-fusion of lamina of first sacral vertebrae: A case report. Journal of Health and Allied Sciences NU. 2012;2(04):60-62. DOI:[10.1055/s-0040-1703615](https://doi.org/10.1055/s-0040-1703615)
9. Pal DR, Rahman MA, Fatema K. Morphometric study of sacral hiatus: A basis for successful caudal epidural block. Bangladesh Journal of Anatomy. 2012;10(1):5-10. DOI:[10.3329/bja.v10i1.15750](https://doi.org/10.3329/bja.v10i1.15750)
10. Dharati K, Nagar SK, Ojaswini M, Dipali T, Paras S, Sucheta P. A study of sacralisation of fifth lumbar vertebra in Gujarat. National Journal of Medical Research. 2012;2(2):211-213.
11. Carlson BM. Human Embryology and Developmental Biology. 5th Ed. Philadelphia: Elsevier (Saunders); 2013:168-174.
12. Moore KL. The Developing Human, Clinically Oriented Embryology, 8th ed. Philadelphia: Saunders, Elsevier; 2008. pp. 350, 387-88.
13. Singh R. Classification causes and clinical implications of sacral spina bifida occulta in Indians. Basic Sci Med. 2013;2(1):14-20. DOI:[10.1096/fasebj.27.1_supplement.746.15](https://doi.org/10.1096/fasebj.27.1_supplement.746.15)
14. Trotter M, Lanier PF. Hiatus canal sacralis in American whites and Negroes. Hum Biol. 1945; 17:368-81.
15. Sekiguchi M, Yabuki S, Satoh K, Kikuchi S. An anatomic study of the sacral hiatus: a basis for successful caudal epidural block. The Clinical journal of pain. 2004;20(1):51-54. DOI:[10.1097/00002508-200401000-00010](https://doi.org/10.1097/00002508-200401000-00010) PMID:14668657
16. Kumar V, Pandey SN, Bajpai RN, Jain PN, Longia GS. Morphometrical study of sacral hiatus. J Anat Soc India. 1992;41(1):7-13.
17. Patel ZK, Thummar B, Rathod SP, Singel TC, Patel S, Zalawadia A. Multi-centric morphometric study of dry human sacrum of Indian population in Gujarat region. NJIRM. 2011;2(2):31-35.
18. Shewale SN, Laeeque M, Kulkarni PR, Diwan CV. Morphological and morphometrical study of sacral hiatus. IJRTSAT. 2013;6(1):48-52.
19. Kiran V, Bhusareddi PS, Harsh MP, Naglikar AS. Agenesis of dorsal wall of sacral canal. Anatomica Karnataka. 2011;5(1):69-71.
20. Senoglu N, Senoglu M, Gumusalan Y. Total spina bifida occulta of the sacrum. International journal of anatomical variations. 2008;1:27-28.
21. Albrecht TL, Scutter SD, Henneberg M. Radiographic method to assess the prevalence of sacral spina bifida occulta. Clinical Anatomy. 2007;20(2):170-174. DOI:[10.1002/ca.20367](https://doi.org/10.1002/ca.20367) PMID:16941459
22. Avrahami E, Frishman E, Fridman Z, Azor M. Spina bifida occulta of S1 is not an innocent finding. Spine. 1994;19(1):12-15. DOI:[10.1097/00007632-199401000-00003](https://doi.org/10.1097/00007632-199401000-00003) PMID:8153797
23. Fidas A, MacDonald HL, Elton RA, McInnes A, Wild SR, Chisholm GD. Prevalence of spina bifida occulta in patients with functional disorders of the lower urinary tract and its relation to urodynamic and neurophysiological measurements. British Medical Journal. 1989;298(6670):357-359. DOI:[10.1136/bmj.298.6670.357](https://doi.org/10.1136/bmj.298.6670.357) PMID:2493933 PMCID:PMC1835713
24. Suma HY, Kulkarni R, Kulkarni RN. A study of sacral hiatus among sacra in South Indian population. Anat Karnataka. 2011; 5:40-4.
25. Bush KE, Hillier S. A controlled study of caudal epidural injections of triamcinolone plus procaine for the management of intractable sciatica. Spine. 1991;16(5):572-575. DOI:[10.1097/00007632-199105000-00015](https://doi.org/10.1097/00007632-199105000-00015) PMID:2053000

How to Cite

Pathak B. A Complete Non-fusion of Sacral Spines- a Rare Anomaly: A Case Report. Journal of Ayurveda Campus. 2023;4(1):89-92.

